

Endoscopic Correction of Frontal Bossing

Bahman Guyuron, M.D.
Michelle Lee, M.D.
Kelsey Larson, M.D.
Bardia Amirlak, M.D.

Cleveland, Ohio;
and Dallas, Texas



Background: Frontal bossing is a displeasing prominence of the supraorbital area. Aesthetic correction has been described as an open surgical technique. This report introduces an endoscopic approach to correction.

Methods: A retrospective review was performed on all patients who underwent endoscopic repair of frontal bossing from 2002 to 2009. Demographics, intraoperative and postoperative course, and outcome variables were collected. Standardized preoperative and postoperative photographs were used for analysis. Aesthetic improvement of the forehead was assessed with a four-point scale (1 = no improvement at all, 4 = significant improvement) by six randomly selected observers. Preoperative facial imaging (lateral skull radiography or computed tomography) was obtained on all patients to assess the thickness of the anterior wall of the frontal sinus.

Results: Ten patients met the study inclusion criteria. Overall, the observers assessed the degree of frontal bossing correction as moderate improvement (2.67 on a four-point scale survey). All endoscopic frontal bossing corrections were performed on an outpatient basis by the senior author (B.G.). No patient was admitted to the hospital for postoperative complications. No complications (such as alopecia, hematoma, contour deformities, or penetration into the frontal sinus) were seen. The limiting factor in achieving optimal outcomes was inadequate thickness of the anterior wall of the frontal sinus. All patients had various concurrent facial rejuvenation procedures.

Conclusions: Endoscopic correction of frontal bossing is an effective and safe surgical technique in forehead aesthetics. This technique is ideal for patients with a mild frontal bossing deformity who have an adequately thick anterior frontal sinus wall. (*Plast. Reconstr. Surg.* 131: 388e, 2013.)

CLINICAL QUESTION/LEVEL OF EVIDENCE: Therapeutic, IV.

Frontal bossing is an unusually prominent forehead over the supraorbital area. Patients with frontal bossing range from those with severe craniofacial anomaly to those with no underlying medical problems. In the pediatric population, frontal bossing is associated with multiple conditions such as Crouzon/Apert syndrome, Hurler syndrome, Pfeiffer syndrome, basal cell nevus syndrome, Russel-Silver syndrome, and certain thalassemias. In the adult population, the most common cause of frontal bossing is acromegaly.¹ Although medical treatments control the progression of acromegaly, physical changes to the skeleton such as frontal bossing are permanent. In female cosmetic patients, frontal bossing masculinizes the facial skeleton and causes aesthetic disharmony.² Many of these patients exhibit hyperaeration of the frontal sinuses on the lateral skull view on computed tomographic scans. Correction of frontal bossing has been described as an open surgical technique where a coronal incision is used for exposure.³ The approach is invasive and can have increased morbidity, large scars, and alopecia. Although endoscopic frontal bone operations such as remodeling of bony defects and removal of osteomas of the frontal bone have been described in the literature, endoscopic frontal bossing correction has not been reported.^{4,5} The objective of this report is to share a simple, safe, and minimally invasive method of improving forehead contour on a properly selected group of patients and to discuss the technique and review the postoperative outcomes.

From the Department of Plastic Surgery, Case Western Reserve University, and the Department of Plastic Surgery, University of Texas Southwestern Medical Center.

Received for publication July 27, 2012; accepted August 29, 2012.

Copyright ©2013 by the American Society of Plastic Surgeons

DOI: 10.1097/PRS.0b013e31827cf6ef

linizes the facial skeleton and causes aesthetic disharmony.² Many of these patients exhibit hyperaeration of the frontal sinuses on the lateral skull view on computed tomographic scans. Correction of frontal bossing has been described as an open surgical technique where a coronal incision is used for exposure.³ The approach is invasive and can have increased morbidity, large scars, and alopecia. Although endoscopic frontal bone operations such as remodeling of bony defects and removal of osteomas of the frontal bone have been described in the literature, endoscopic frontal bossing correction has not been reported.^{4,5} The objective of this report is to share a simple, safe, and minimally invasive method of improving forehead contour on a properly selected group of patients and to discuss the technique and review the postoperative outcomes.

Disclosure: The authors have no financial interest to declare in relation to the content of this article.

PATIENTS AND METHODS

Institutional review board approval was obtained for this retrospective study. Charts for all patients who had undergone endoscopic repair of frontal bossing from 2002 to 2009 by the senior author (B.G.) were reviewed. Patients were included in the study if they met the following criteria: at least 18 years old, at least 6 months of follow-up, and adequate preoperative and postoperative photographs. Patients who were younger than 18, without adequate preoperative and postoperative photographs, and had less than 6 months of follow-up were excluded from the study. Data points collected included demographics, intraoperative and postoperative course, and outcome variables. Standardized preoperative and postoperative photographs were used for analysis. Aesthetic improvement of the forehead was assessed with a photographic review completed by six randomly selected observers. The reviewers assessed the degree of frontal bossing correction with a four-point scale (i.e., 1, no improvement; 2, slight improvement; 3, moderate improvement; and 4, significant improvement). Statistical analysis was performed using GraphPad Prism 3.02 (GraphPad Software, Inc., La Jolla, Calif.).

Surgical Technique

Preoperative facial imaging (lateral skull radiography or computed tomography) was obtained on all patients to assess the thickness of the anterior wall of the frontal sinus (Fig. 1). A midline incision was marked approximately 0.5 cm behind

the hairline. Two temporal incisions were marked at approximately 7 and 10 cm from the midline when a concomitant forehead rejuvenation was intended. Otherwise, the incisions were limited to a total of three, one central and two lateral. All incisions were radial and 1.2 to 1.5 cm in length, depending on the thickness of the scalp. The lateral incisions were taken through the superficial

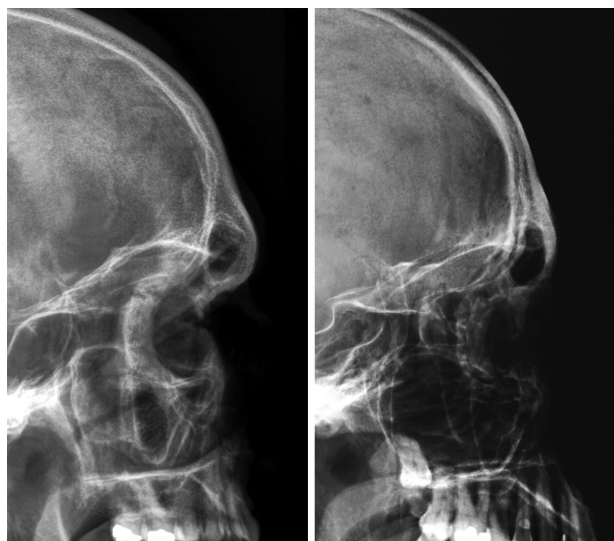


Fig. 1. Preoperative lateral skull radiographs to assess the thickness of the frontal bone.

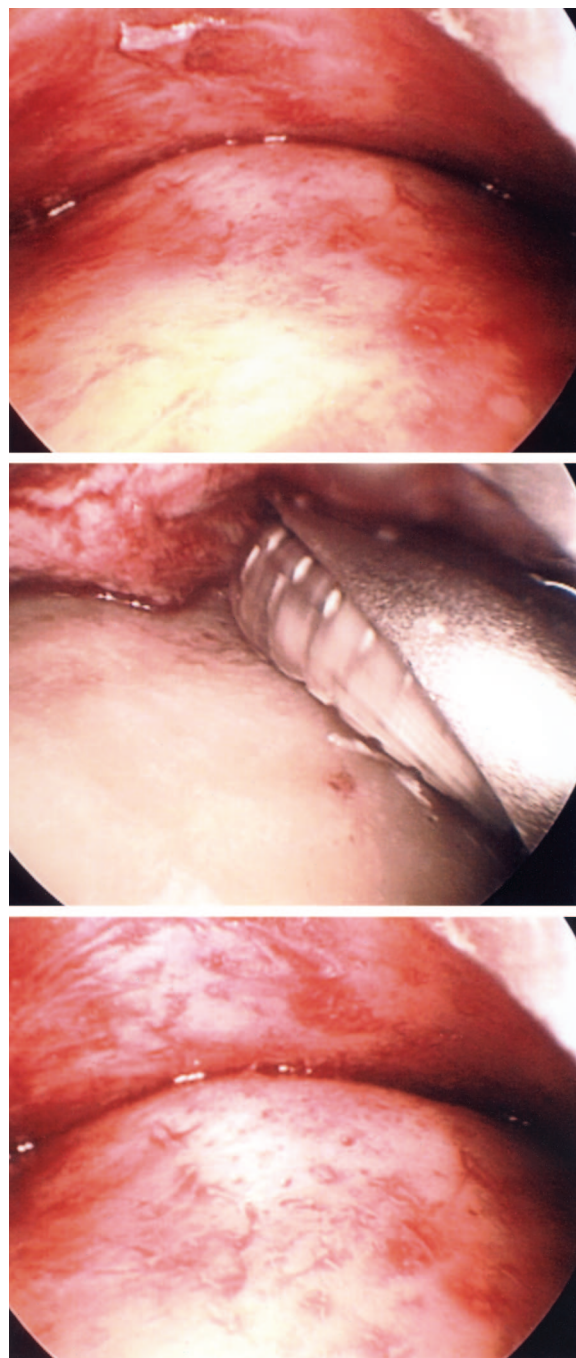


Fig. 2. Intraoperative photographs of endoscopic frontal bossing correction.

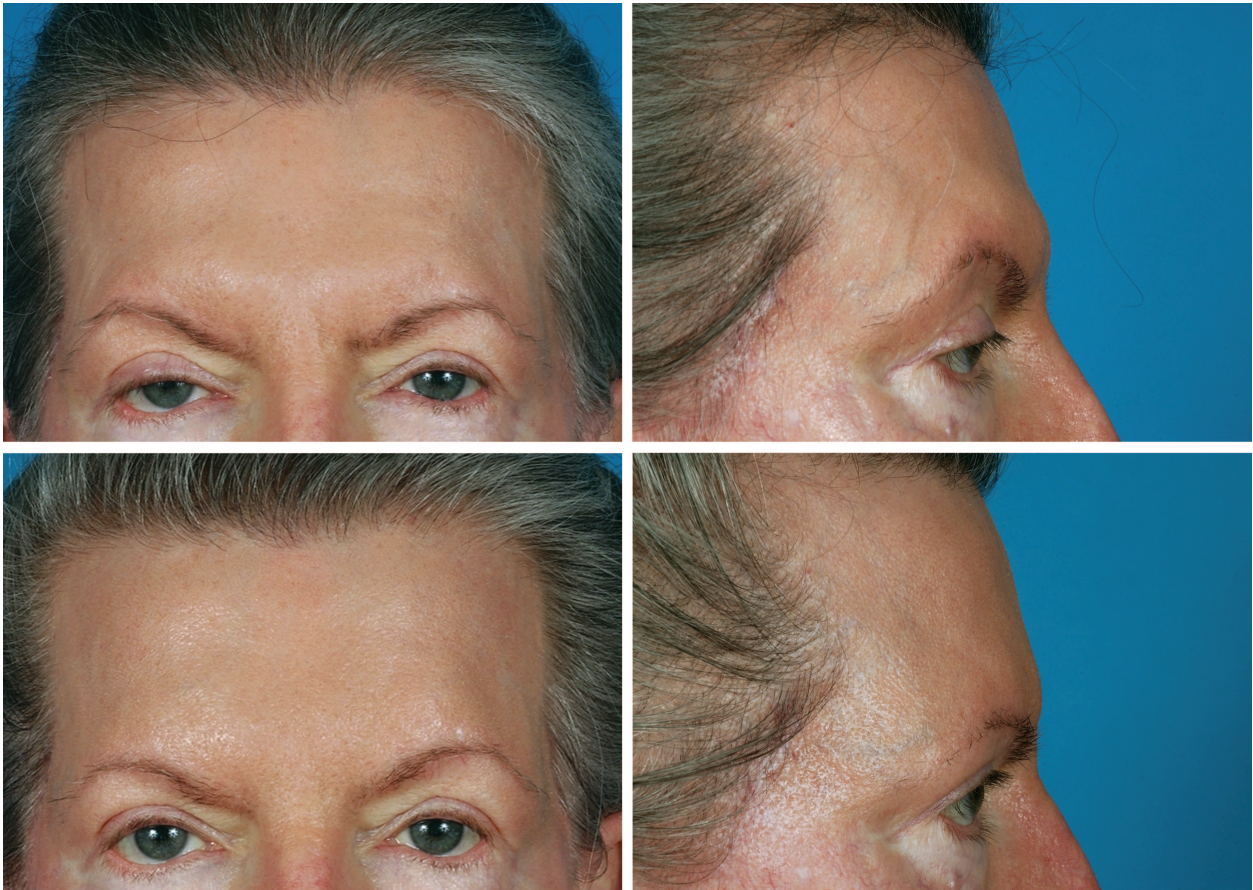

Fig. 3. Preoperative and 2-year postoperative frontal and lateral photographs of the forehead after endoscopic frontal bossing correction.

temporal fascia, exposing the deep temporal fascia. The midline and the intermediate (7 cm from the midline) incisions were carried down to periosteum. Endoscopic access devices (Applied Medical Technology, Inc., Brecksville, Ohio) were then inserted through all the incisions. The dissected plane was subperiosteal in the central forehead area and superficial to the deep temporalis fascia in the temple region. Lateral incisions and dissection superficial to the deep temporal fascia was completed for the patients undergoing forehead rejuvenation. A 30-degree 4-mm scope (Karl Storz, Inc., Tuttlingen, Germany) was introduced through the endoscopic access device. The dissection was continued toward the supraorbital rim using the endoscope. As the dissection was advanced medially, the supraorbital nerve, supraorbital vessels, and supratrochlear nerve were identified and protected. A sterling oval burr and shaver (ConMed Linvatec, Utica, N.Y.) with the attached irrigation device were used to contour the frontal bossing. Contouring of the frontal bone was assessed by a combination of visual in-

spection and palpation (Fig. 2). Meticulous attention must be paid to preoperative radiographs, as these images help to prevent penetration into the frontal sinus. The frontal sinus should never be visualized through the thin frontal bone. If the frontal bone has become transparent, excessive contouring has occurred and must cease. Small inadvertent entrance into the frontal sinus may be observed. Larger penetration into the sinus may require cranioplasty and obliteration of the frontal sinus. For patients who request concurrent full forehead rejuvenation, the following steps are added: (1) an additional incision is made 3 cm caudolateral to the temple incision to suspend the fascia; (2) the arcus marginalis and the periorbital are released along the entire supraorbital rim using a longer periosteal elevator; (3) the periosteum along the lateral orbital rim is released along the lateral orbital wall; and (4) the corrugator supercillii, depressor supercillii, and medial borders of the procerus muscles are removed and replaced with fat from the area cephalad to the zygoma and deep to the temporalis muscle.⁶

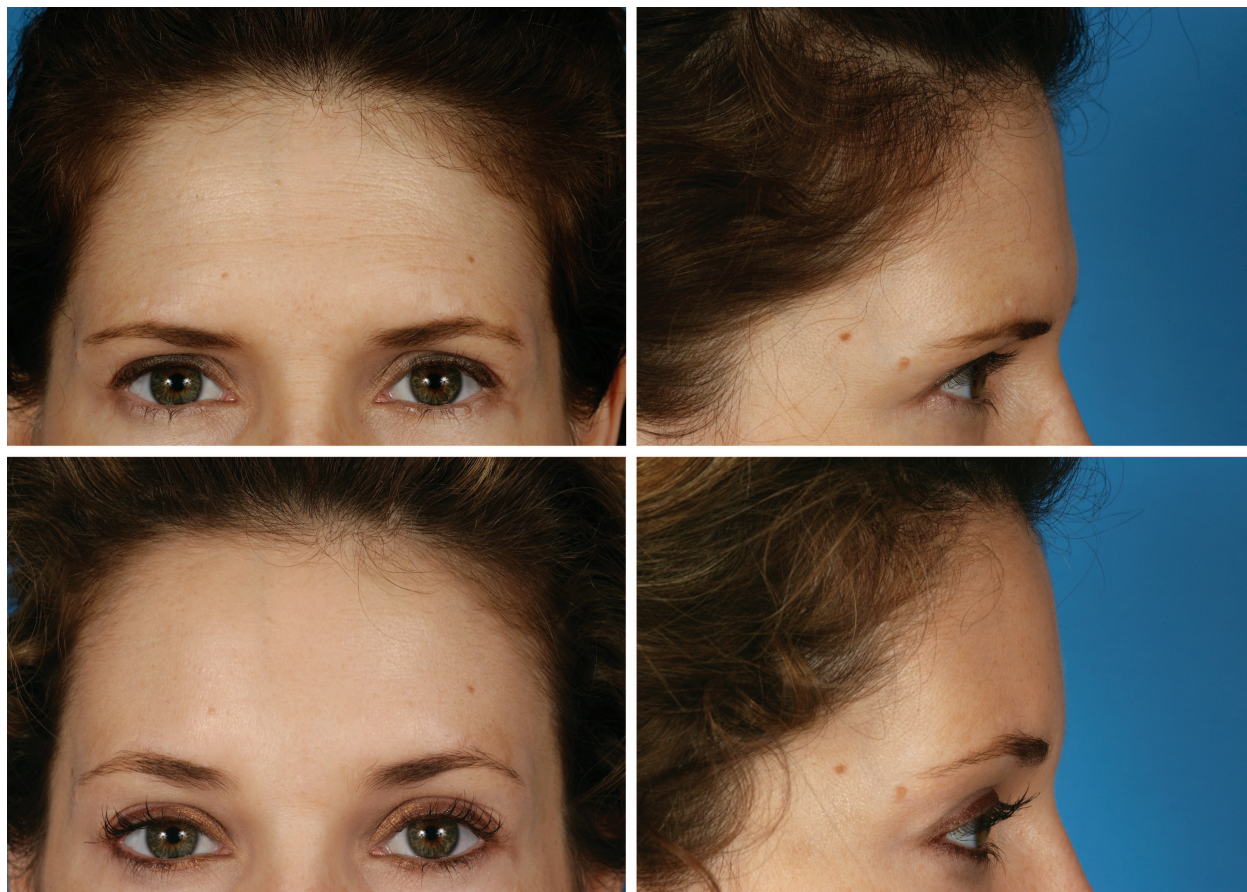

Fig. 4. Preoperative and 1-year postoperative frontal and lateral photographs of the forehead after endoscopic frontal bossing correction.

RESULTS

Ten patients met the study inclusion criteria. The majority of patients were male (six of 10). All patients were healthy, with no associated medical comorbidities. All endoscopic frontal bossing corrections were performed on an outpatient basis by the senior author (B.G.). No patient was admitted to the hospital for postoperative complications. No complications such as alopecia, hematoma, contour deformities, or penetration into the frontal sinus were seen. The limiting factor in achieving optimal outcomes was inadequate thickness of the anterior wall of the frontal sinus. All patients had various concurrent facial rejuvenation procedures (Figs. 3 through 5). However, analyzing only the forehead, the observers assessed the degree of frontal bossing correction as moderate improvement (2.67 on a four-point scale survey; range 1 to 4) (Table 1).

DISCUSSION

Approaches to the forehead skeleton have traditionally been through a bicoronal incision.⁷ Al-

though the open approach with osteotomy of the anterior table of the frontal sinus wall provides excellent outcome and remains the best choice for correction of severe frontal bossing, common complications include long scars, alopecia, increased risk of blood loss, forehead paresthesias, painful neuromas and traction palsy of the facial nerve, and long coronal scar, which makes this operation less desirable for mild to moderate frontal bossing.⁸ The introduction of the endoscope revolutionized the surgical approach to the forehead, as it allowed for smaller incisions, magnified visualization, decreased risk of bleeding, faster recovery, and decreased chance of neuropathy by preserving cutaneous nerves.⁹ The endoscope has been used widely in craniomaxillofacial and facial aesthetic surgery. Applications include Le Fort I and III, mandibular osteotomies, facial fracture repairs, endoscopic face lifts, and forehead lifts.^{4,10}

Endoscopic contouring of the forehead was first described by Song et al. on a Korean woman with frontal bone deformities.¹¹ Since then, most published endoscopic manipulation of the frontal

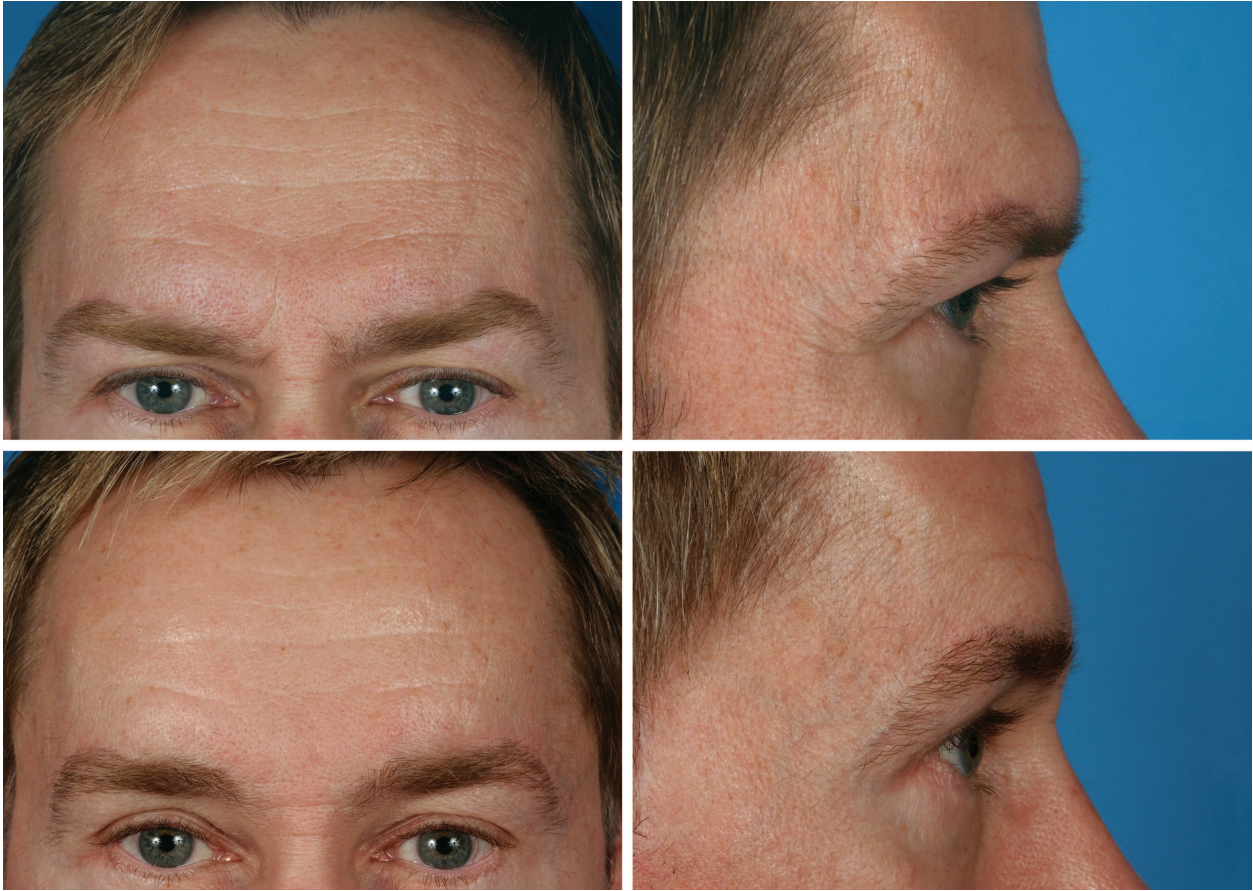

Fig. 5. Preoperative and 4-year postoperative frontal and lateral photographs of the forehead after endoscopic frontal bossing correction.

Table 1. Average Rating of Frontal Bossing Improvement Assessed by Six Randomly Selected Observers

Patient	Average FB Improvement*
1	3.3
2	2.8
3	2.5
4	1.3
5	2.3
6	2.5
7	2.1
8	3.5
9	3.5
10	3.3

FB, frontal bossing.

*Scale: 1, no improvement; 2, slight improvement; 3, moderate improvement; and 4, significant improvement.

bone and supraorbital ridge has involved osteoma/mass excision or frontal sinus fracture repair.^{5,12-16} To our knowledge, this is the first case series of endoscopic correction of frontal bossing with postoperative follow-up and aesthetic assessment. The senior author has been using this technique for the correction of frontal bossing for the past de-

cade. Retrospective review of those patients confirms adequate aesthetic correction and minimal postoperative morbidity. Ideal patients for endoscopic frontal bossing correction are those with mild deformity and adequate anterior table thickness over the frontal sinus. Potential complications include neurosensory damage, vascular injury, and excessive operative time. The incision and dissection planes for this technique are similar to the standard endoscopic forehead lift. This similarity allows easy access to the frontal bone for contouring in patients with frontal bossing and undergoing concurrent forehead rejuvenation. This work underscores the reproducibility, reliability, and efficacy of endoscopic manipulation of the forehead bone in select patients. Although the technique is simple, a short period is required for one to become accustomed to the use of the burr and the shaver.

CONCLUSIONS

In patients with adequate anterior frontal sinus wall thickness and mild to moderate deformity, endoscopic correction of frontal bossing is a minimally

invasive, effective, and safe surgical technique for improving forehead aesthetics. It produces acceptable aesthetic results, with reduced morbidity. Although no complications were observed in this small group of patients, studies on a larger patient population may provide more convincing evidence for efficacy and safety of this operation.

Bahman Guyuron, M.D.

Department of Plastic Surgery
Case Western Reserve University
29017 Cedar Road
Cleveland, Ohio 44124
bahman.guyuron@gmail.com

PATIENT CONSENT

Patients provided written consent for the use of their images.

REFERENCES

1. Converse JM, Baker DC. Surgical correction of the facial deformities of acromegaly. *Ann Plast Surg.* 1978;1:612–616.
2. Ousterhout DK. Dr. Paul Tessier and facial skeletal masculinization. *Ann Plast Surg.* 2011;67:S10–S15.
3. Wagner W, Wiewrodt D. A simple technique for the correction of frontal bossing in synostotic scaphocephaly. *Childs Nerv Syst.* 2008;24:373–377.
4. Park DH, Lee JW, Song CH, Han DG, Ahn KY. Endoscopic application in aesthetic and reconstructive facial bone surgery. *Plast Reconstr Surg.* 1998;102:1199–1209.
5. Lai CH, Sun IF, Huang SH, Lai CS, Lin SD. Forehead osteoma excision by endoscopic approach. *Ann Plast Surg.* 2008;61:533–536.
6. Guyuron B, Rose K. Harvesting fat from the infratemporal fossa. *Plast Reconstr Surg.* 2004;114:245–249.
7. Ortiz Monasterio F. Aesthetic surgery of the facial skeleton: The forehead. *Clin Plast Surg.* 1991;18:19–27.
8. Eppley BL, Custer PL, Sadove AM. Cutaneous approaches to the orbital skeleton and periorbital structures. *J Oral Maxillofac Surg.* 1990;48:842–854.
9. Ramirez OM. Endoscopic techniques in facial rejuvenation: An overview. Part I. *Aesthetic Plast Surg.* 1994;18:141–147.
10. Lee CH, Lee C, Trabulsy PP. Endoscopic-assisted repair of a malar fracture. *Ann Plast Surg.* 1996;37:178–183.
11. Song IC, Pozner JN, Sadeh AE, Shin MS. Endoscopic-assisted recontouring of the facial skeleton: The forehead. *Ann Plast Surg.* 1995;34:323–325; discussion 325.
12. Cai Q, Zhang XM, Su ZZ. One case on excision of huge orbital osteoma by endoscopic Caldwell-LuC approach and external nasal frontal sinus approach (in Chinese). *Zhonghua Er Bi Yan Hou Tou Jing Wai Ke Za Zhi* 2005;40:430.
13. Chen C, Selva D, Wormald PJ. Endoscopic modified lothrop procedure: An alternative for frontal osteoma excision. *Rhinology* 2004;42:239–243.
14. Onishi K, Maruyama Y, Sawaizumi M. Endoscopic excision of forehead osteoma. *J Craniofac Surg.* 1995;6:516–518.
15. Graham HD III, Spring P. Endoscopic repair of frontal sinus fracture: Case report. *J Craniomaxillofac Trauma* 1996; 2:52–55.
16. Cronin ED, Ruiz-Razura A, Livingston CK, Katzen JT. Endoscopic approach for the resection of forehead masses. *Plast Reconstr Surg.* 2000;105:2459–2463.